

PATIENT PRESENTING CLINICAL SIGNS

Gilbert Kraeutler

History: 2-3/4 murmur change in ~10 months

SPECIES ECHOCARDIOGRAPHIC FINDINGS

Canine

2D, M-mode, and Doppler study.

BREED

Chihuahua Mix

Left atrial size is normal. The mitral valve leaflets are mildly thickened, and a mild jet of eccentric mitral regurgitation is present. Left ventricular dimensions are normal. Left ventricular systolic function is normal. The aorta and aortic are normal. Right atrial and right ventricular dimensions are normal. The tricuspid valve appears normal, though trace tricuspid regurgitation is present. The pulmonary artery and pulmonic valve are normal. No pericardial effusion or cardiac masses are seen.

SEX

Male Neutered

LA - 25.0 mm
LVIDd - 24.0 mm
LVIDs - 15.2 mm
FS - 36.6%
RA - 19.3 mm
LVOT - 1.31 m/s
RVOT - 0.73 m/s

AGE

10 years

WEIGHT

19.8 lbs

ASSESSMENT/RECOMMENDATIONS

Degenerative mitral valve disease

INTERPRETED BY

Keith Blass, DVM,
MS, DACVIM

This examination demonstrates mild regurgitation of blood across Gilbert's mitral valve resulting from degenerative valve disease. The hemodynamic effects of the regurgitation also appear to be mild, as Gilbert does not have secondary dilation of either of his left heart chambers. As such, Gilbert's mitral valve disease appears to be well-compensated, and his current risk for the development of clinical signs secondary to it (ex. coughing, exercise intolerance, syncope, labored breathing) appears to be low.

IMAGING PERFORMED BY

Rebekah Jakum, CVT
ARDMS/RVT

No therapy is recommended at this stage of Gilbert's mitral valve disease.

A recheck echocardiogram is recommended in 6 months to monitor for disease progression.

HOSPITAL NAME

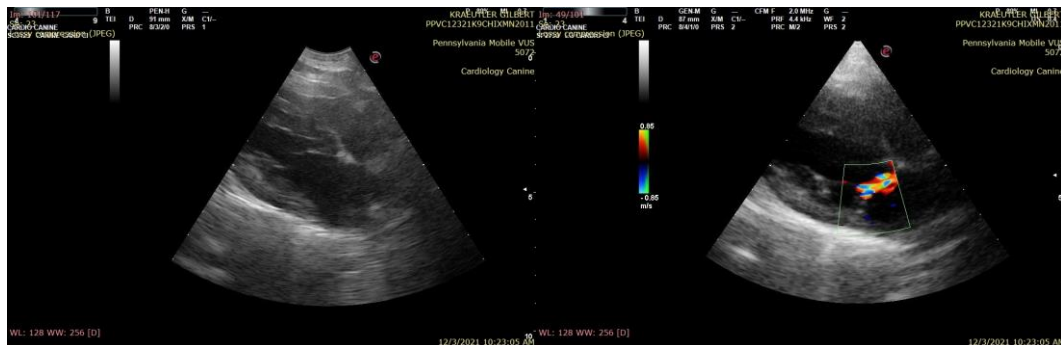Pocono Peak VC

REFERRING VET

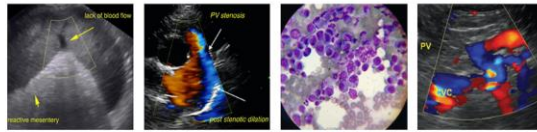
Dr. Coyle

DATE

12.3.2021



The information and recommendations provided are based on the images presented by the referring veterinarian. No evaluation can be communicated regarding pathology that was not visible in the image/video clips provided.



PATIENT

Gilbert Kraeutler

Thank you for this referral. If the clinical or image interpretation does not parallel your findings or if I can be of any further assistance please contact me.

SPECIES

Canine

Keith Blass, DVM, MS, DACVIM (Cardiology)

KeithBlass@gmail.com

631-804-5754

BREED

Chihuahua Mix

SEX

Male Neutered

AGE

10 years

WEIGHT

19.8 lbs

INTERPRETED BY

Keith Blass, DVM,
MS, DACVIM

**IMAGING
PERFORMED BY**

Rebekah Jakum, CVT
ARDMS/RVT

HOSPITAL NAME

Pocono Peak VC

REFERRING VET

Dr. Coyle

DATE

12.3.2021